Acta neurol. belg., 2007, **107**, 26-31

Neurodegeneration with brain iron accumulation : clinical, radiographic and genetic heterogeneity and corresponding therapeutic options

Frederik CLEMENT[1,3], David DEVOS[1], Caroline MOREAU[1], Philippe COUBES[2], Alain DESTEE[1] and Luc DEFEBVRE[1]

[1]Department of Neurology, Hôpital Roger Salengro, Lille, France ; [2]Department of Neurosurgery, Centre Gui de Chaulwiac, Montpellier, France ; [3]Department of Neuroradiology, H. Hart Ziekenhuis Roeselare-Menen, Belgium.

Abstract

Background : Neurodegeneration with brain iron accumulation (NBIA), formerly known as Hallervorden-Spatz syndrome, is a heterogeneous group of disorders with different treatment options.

Case reports : In the first case, progressively generalizing dystonic symptoms appeared during childhood. A mutation in the gene encoding pantothenate kinase 2 (PANK2) was found. Brain MRI showed bilateral hypersignals within the globus pallidi on T2-weighted images. The patient was successfully treated by pallidal deep brain stimulation (DBS). In the second case an adult onset with parkinsonism was observed, for which no PANK2 mutation was found. T2-weighted brain MR images revealed multiple significant hyposignals (suggestive of iron deposits) localised in the cerebellar dentate nuclei and in the globi pallidi, the red nuclei and the substantia nigra. An antiparkinsonian treatment was proposed.

Conclusion : The clinical, radiographic and genetic heterogeneity of NBIA has to be underlined.

Key words : Neurodegeneration ; iron ; dystonia ; pantothenate kinase ; deep brain stimulation.

Introduction

Neurodegeneration with brain iron accumulation (NBIA) triggers cerebral neurodegeneration via iron deposition in the basal ganglia. It is a group of disorders with different onset times and heterogeneous clinical presentations (Carod-Artal *et al.*, 2004). Patients with NBIA have a combination of motor symptoms - notably dystonia, parkinsonism, choreoathetosis, corticospinal tract involvement, optic atrophy, pigmentary retinopathy and cognitive impairment. Following the recent identification of mutations in the PANK2 gene on chromosome 20p12.3-p13 in some patients with the NBIA phenotype, the term pantothenate kinase-associated neurodegeneration has been proposed (Thomas *et al.*, 2004). We compare the clinical, radiographic and genetic features of two patients and discuss different therapeutic approaches. In the first patient, the symptoms appeared during childhood period, whereas adult onset was observed in the second patient.

Case reports

PATIENT 1

A 14-year-old, right-handed boy consulted for the first time in our department because of dystonic right arm movements experienced over the previous three years. The condition had deteriorated progressively and had finally resulted in a significant functional deficit, making writing impossible. The patient's medical history included flat feet and distortion of the left ankle at the age of 18 months. Pregnancy, delivery and the subject's psychomotor development during the first decade had been completely normal. The patient's father had died at the age of 40 due to the complications of diabetes mellitus but the patient's mother and his two older sisters had never suffered from any major medical problems. There was no family history of neurological disorder.

At the first clinical examination in 1997, we observed intermittent, dystonic movements with internal rotation of the right arm and wrist hyperextension, which worsened during writing. Indeed, writing was only possible when the arm was stretched out. Moderate hypokinesia was present : the patient had difficulty in performing fine movements with the fingers of either hand. Both knee tendon reflexes were brisk. Moderate dysarthria with dystonic characteristics was noticed. All the other neurological findings were normal. Neuropsychological investigations revealed modest intellectual capacities with an IQ score of 91 on the revised Wechsler Intelligence Scale for Children.

Brain MRI showed bilateral hypersignals within the globi pallidi on T2-weighted images but no atrophy, no vascular lesions and no calcifications (Fig. 1).

The differential diagnosis of this clinical presentation includes both the spectrum of inborn errors of metabolism and that of neurodegenerative

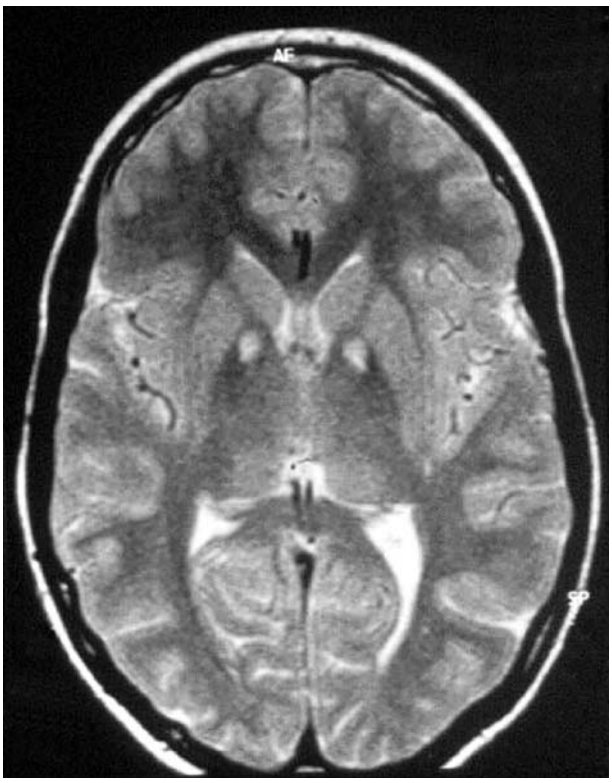

FIG. 1. — Hypersignals bilaterally within the globi pallidi on T2-images.

disorders with potential early onset. In both groups, various possibilities were ruled out on clinical, biochemical, genetic and radiographic grounds. In the absence of any evidence for other neurodegenerative or metabolic diseases we concluded that Hallervorden-Spatz disease was the most probable hypothesis. Then, in 2003, we found a mutation in the patient's PANK2 gene, thus definitively confirming the diagnosis of Hallervorden-Spatz disease or pantothenate kinase-associated neurodegeneration.

The neurological symptoms remained stable for more than six months after the first consultation. During this period, patient was treated with a dopamine agonist (bromocriptine, 30 mg/day) and low doses of levodopa (300 mg/day). However, after one year, he presented oromandibular dystonia and spastic dysphonia of fluctuating intensity. Dystonic arm movements were also variable and now appeared to be more prominent in the left hand - exactly the opposite of the initial observations. An anticholinergic agent (trihexyfenidylhydrochloride, 15 mg/day) was combined with the ongoing drug treatment. Two years later, axial dystonia with scoliotic deformation was noticed. Oromandibular dystonia persisted, causing mastication difficulties. Gait problems were relatively mild, with discrete *pes equinovarus* on the right side. Oromandibular and left arm dystonia were treated with botulinum toxin injections. These injections temporarily improved mastication and swallowing but the effect on dysphonia was much less pronounced. Five years after the first visit, further worsening was marked by significant aggravation of right arm dystonia. Axial dystonia also increased (especially at the neck level), leading to an extended posture of the neck. MRI monitoring over this five-year period did not reveal any ongoing modifications. Nine years after the first neuropsychological evaluation, an IQ score of 82 was obtained on the revised Wechsler Adult Intelligence Survey scale. Anticholinergic treatment was increased (trihexyfenidylhydrochloride up to 60 mg/day) and dopamine agonist treatment (bromocriptine) was first decreased and then finally stopped.

Due to the rise in dystonic symptoms despite conservative treatment, the patient underwent a neurosurgical operation for bilateral stimulation of the globus pallidum internum (Gpi). The operation was performed under standard, general anaesthesia. A pair of electrodes (each comprising four contacts numbered conventionally from 0 (distal) to 3 (proximal)) was implanted bilaterally. The surgical procedure was problem-free. Five months after the operation, a progressive improvement in the axial dystonia was noticed, leading to a more stable gait. Dystonic symptoms in the limbs decreased only slightly at first but a marked improvement of the right arm was noticed twelve months after the operation. The patient was then able to write again. Dystonia of the face was also less pronounced, although mastication difficulties and dysphonia remained. Eighteen months after the operation, evaluation of the dystonic syndrome revealed a Burke-Fahn-Marsden (BFM) score of 19/120 and a functional score of 8/30, compared to a BFM score of 55/120 and a functional score of 11/30 before the operation. Levodopa treatment was reduced. In June 2004, the stimulation frequency (130 Hertz), pulse width (450 ms) and amplitude (1,5 Volt) were equalized on both the right and left side. Levodopa treatment was stopped and the anticholinergic treatment was reduced. The social outcome also happened to be favourable : the patient obtained his driver's license and qualified as an accountant. In June 2005 we noticed no further aggravation of the symptoms and reduction of anticholinergic treatment was continued. The patient was professionally active in the financial department of the local authorities.

PATIENT 2

A 47-year-old, professionally active woman (working as a secretary) consulted in our department because of involuntary buccolingual and facial movements. The patient's medical history included asthma, herniated disc, migraine and transitory tics (eye blinking) during childhood. She had never taken neuroleptic drugs. One of her two

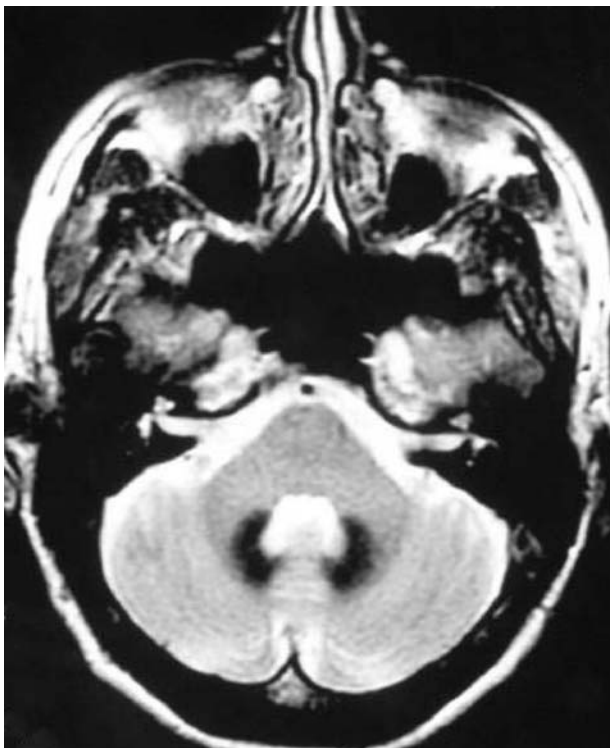

FIG. 2. — Hyposignals, evocative for iron deposits, localised in the dentate nuclei of the cerebellum on T2-images.

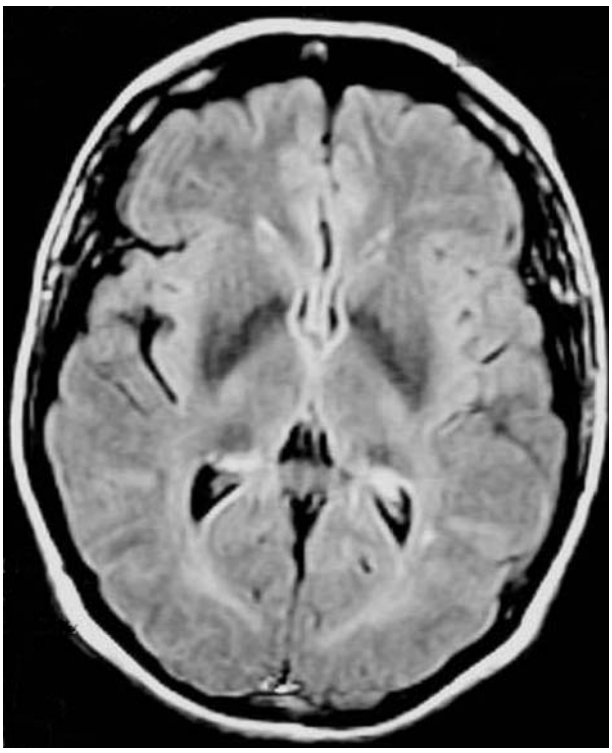

FIG. 3. — Hyposignals, evocative for iron deposits, localised in the globi pallidi on T2-images.

sisters experienced involuntary movements of the cheek (starting at the age of 40) and she had also suffered from severe depression. The patient's father presented behavioural problems and motor agitation. The patient's paternal grandmother may have presented an episode of Sydenham's chorea but died due to phlebitis.

The patient's history of movement disorders had started more than ten years before the first consultation, with the appearance of a left arm action tremor with mainly postural characteristics, relatively stable since then. In the six months before consultation, the patient had started experiencing difficulty in swallowing. Later on, dysarthria and mastication problems were noticed. This was linked to the presence of involuntary buccolingual, pharyngeal and facial movements.

At the first clinical examination in December 2002, a gait pattern with extrapyramidal characteristics (marked by a discrete anteflexion of the trunk) was noted. Akinesia and rigidity predominated on the right side. Facial expression was less varied and hyperkinetic dysarthria was present. Dystonic buccolingual, pharyngeal and facial movements were noted : these appeared spontaneously but were also provoked by voluntary movement. Deep tendon reflexes were brisk, and both Hoffmann and Babinski signs were present. Finally, there was an action and postural tremor of both arms, with discrete dysmetria. All other neurological findings were normal. A cognitive evaluation appeared to be completely normal, since the following scores were obtained : a Mini Mental State Examination score of 29/30, a Mattis score of 144/144, a BREF score (frontal battery of psychological tests) of 17/18 and an IQ score of 87. The extrapyramidal syndrome appeared to be levodopa-responsive : following administration of 200 mg of levodopa, the motor UPDRS score decreased by 86%, passing from 17 to 4. Levodopa treatment (400 mg/day) was initiated and indeed induced a significant improvement not only in the dysarthria but also terms of the akinesia, rigidity and dystonia.

No mutations in the DYT gene were found and there was no genetic evidence of Huntington's disease. T2-weighted brain MRI images showed significant hyposignals (suggestive of iron deposits) localised not only in the cerebellar dentate nuclei (Fig. 2) but also in the globi pallidi (Fig. 3), the red nuclei and the substantia nigra (Fig. 4). We ruled out neuroferritinopathy and aceruloplasminemia, both adult-onset, genetic, extrapyramidal disorders associated with increased iron accumulation in the brain. Finally, the possibility of neurodegeneration with brain iron accumulation was considered, even though no mutations in the PANK2 gene had been found. Further progression of the condition was marked by the appearance of dystonic right arm movements, especially when writing. An anticholinergic drug (trihexyfenidylhydrochloride) was

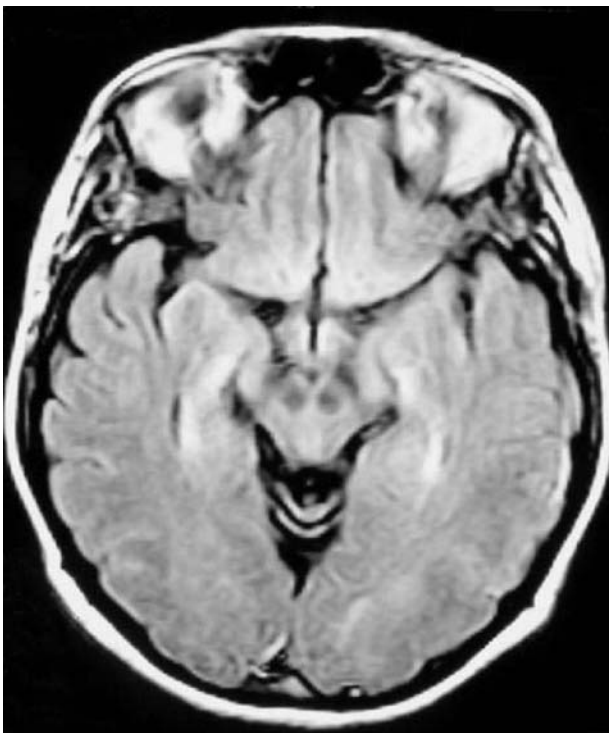

FIG. 4. — Hyposignals, evocative for iron deposits, localised in the substantia nigra and red nuclei on T2-images.

initially combined with the ongoing drug treatment but was replaced by baclofen (15 mg/day) after the occurrence of side-effects. Levodopa treatment was progressively increased up to 800 mg/day. At a recent consultation (June 2005), dystonic and parkinsonian symptoms happened to be stabilized and thus treatment was not modified.

Discussion

Neurodegeneration with brain iron accumulation (NBIA, formerly known as Hallervorden-Spatz syndrome) is a heterogeneous group of disorders. A distinction must made between patients who bear mutations in the gene encoding pantothenate kinase 2 (PANK2) and those who do not. For disorders associated with PANK2 mutations, the term pantothenate kinase-associated neurodegeneration is now routinely used (Hayflick, 2003). Hallervorden-Spatz disease with early onset and rapid progression is the originally reported, classic form, as described in 1922 in a family of 12 siblings, with 5 individuals affected at the age between 7 and 9 years. This appears to be an autosomal, recessive neurodegenerative disorder, associated with iron accumulation in the globus pallidus, substantia nigra pars reticulata, with demyelination of the globus pallidus and widespread focal, axonal swellings in the pallidonigral system and the cerebral cortex (Hallervorden and Spatz, 1922). Although childhood-onset cases are the most common type of NBIA, adolescent- and adult-onset presentations have also been reported. Clinical symptoms vary greatly amongst patients and may notably include extrapyramidal signs (dystonia, bradykinesia, rigidity, tremor, choreoathetosis, dysarthria) as well as ataxia, seizures, dementia, visual impairment due to retinitis pigmentosa or indeed pyramidal signs like spasticity and hyperreflexia (Wigboldus and Bruyn 1968).

In patients with the classic form of NBIA (age of onset ranging from 0.5 to 12 years), dystonia is almost always an early manifestation. Early dystonia often involves the cranial and limb musculature, whereas axial dystonia predominates in later symptoms – as seen in our first patient. Other prominent features include dysarthria (also noticed here), rigidity and choreoathetosis. Cognitive decline (29%) and involvement of the corticospinal tract (25%) are also common (Hayflick *et al.*, 2003). Our young patient showed normal intellectual development during childhood. An IQ score of 91 was noted at the first evaluation, and nine years later a score of 82 was achieved. Follow-up of this subject's cognitive state will be an important source of information. Apart from hyperreflexia of the legs, no pyramidal signs were observed. Hayflick found clinical or electroretinographic evidence of retinopathy present in 68% of patients with the classic disease variant (Hayflick *et al.*, 2003). Our first patient had a normal electroretinogram. Adult-onset cases have a quite variable clinical presentation (Halliday 1995). Parkinsonism is a predominant feature (Jankovic *et al.*, 1985 ; Grimes *et al.*, 2000 ; Racette *et al.*, 2001 ; Thomas *et al.*, 2004), as noticed in our second case. Dementia is also often presented (Dooling *et al.*, 1974 ; Jankovic *et al.*, 1985 ; Wang *et al.*, 1990), although to date our second patient has not shown any cognitive decline.

MRI has been useful in the diagnosis of iron storage diseases. Iron, a paramagnetic substance, exerts a proton relaxation effect on neighbouring hydrogen nuclei, resulting in a decrease in T1 and T2 times. On T2-weighted images, the decrease in relaxation time results in a decreased signal. The low attenuation localized bilaterally in the globus pallidi suggests iron accumulation. The central, high signal within the hypodense zone may be due to intense gliosis or increased water content due to loss of cellular elements. This specific, hyperintensity pattern within the hypointense medial globus pallidus is known as the "eye of the tiger" sign (Sethi *et al.*, 1998). In our first case, the first MRI revealed bilateral hypersignals within the globus pallidi on T2-weighted images. Monitoring brain MRI parameters over the next five years did not reveal any further modifications. An area of only high signal intensity on T2-weighted images (i.e. without any neighbouring hypodensity) may be

evident in the earlier stages and may become progressively smaller (Thomas *et al*., 2004). Gallucci and colleagues found that the MRI characteristics may change over the course of the disease. They give an example of a case with hyperintense pallidi which, over a period of 3 years, changed to a mixed-intensity, target-like appearance and then finally to the pattern known as the "eye of the tiger" (Gallucci *et al*., 1990). This pattern is not found in all patients with NBIA syndrome. MRI images of some patients show only T2-weighted hypointensity in the globus pallidus, without a central hypersignal : iron deposition in the red nucleus and dentate nucleus are common features in this group (Hayflick *et al*., 2003). This MRI feature with multiple significant hyposignals was noticed in our second patient.

The first case corresponds to the classic NBIA syndrome, as we described earlier, and indeed a PANK2 mutation was found. Hayflick and colleagues have identified PANK2 mutations in a large subgroup of patients with NBIA syndrome. They found that all patients with the classic disease and one third of those with atypical disease had PANK2 mutations. The clinical features of the PANK2-mutation-positive patients with the classic disease were remarkably homogeneous, whilst those of patients with atypical NBIA syndrome and PANK2 mutations were heterogeneous (Hayflick *et al*., 2003). The presence of a mutation in the PANK2 gene is usually associated with younger age at onset and a higher frequency of dystonia, dysarthria, intellectual impairment and gait disturbance. The absence of a mutation in the PANK2 gene tends to be associated with onset of symptoms after the age of 20 and with parkinsonism, which was observed in the second PANK2-mutation-negative patient (Thomas *et al*., 2004). Once the PANK2 gene had been discovered on chromosome 20, it was found to code for pantothenate kinase – an essential enzyme in the synthesis of coenzyme A from pantothenate. Coenzyme A plays a central role in fatty acid synthesis and energy metabolism. A deficiency can lead first to a high concentration of cysteine in the basal ganglia and then to iron accumulation in these same areas. The cysteine-iron complex results in tissue damage by provoking oxidative stress (Gordon, 2002). Both iron accumulation and the loss of cellular elements explain the typical "eye of the tiger" pattern on T2-weighted brain MRI images. The study by Hayflick and colleagues found this pattern in all patients with pantothenate kinase-associated neurodegeneration, regardless of classic or atypical clinical presentation. No evidence of the eye-of-the-tiger pattern was found in PANK2 mutation-negative patients (Hayflick *et al*., 2003). The diversity of the lesions in this group of patients correlates with the clinical heterogeneity. MRI of our second patient showed multiple lesions without eye-of-the-tiger pattern.

Our adult patient's extrapyramidal syndrome appeared to be levodopa-responsive. This has also been described in other adult-onset cases (Seibel *et al.,* 1993 ; Carod-Artal *et al.*, 2004). Anticholinergic therapy (even at high doses) did not influence our patients' symptomatology. In our first subject, dopaminergic treatment had no effect on the clinical symptoms. The botulinum injections that were subsequently given to treat the patient's oromandibular dystonia temporarily improved mastication and swallowing. Other authors have mentioned the benefit of botulinum toxin for treatment of jaw-opening dystonia in Hallervorden-Spatz syndrome (Dressler *et al*., 2001). The general dystonic symptoms were finally treated by pallidal deep brain stimulation (DBS). Electrical stimulation of the globus pallidum internum (Gpi) has been proven to be an effective treatment for primary generalized dystonia (PGD), especially in DYT1 mutation carriers, and should be considered for conditions which are refractory to drug therapy (Vercueil *et al*., 2002). Coubes and colleagues found that the improvement of both clinical and functional Burke-Fahn-Marsden (BFM) scores at the 2-year follow-up examination was comparable for PGD patients with and without the DYT1 mutation (Coubes *et al*., 2004). The efficacy and safety of chronic, pallidal DBS in generalized non-DYT1 dystonia has been confirmed by other authors. Beneficial results have been achieved in patients with primary genetic segmental dystonia, myoclonic dystonia and complex cervical dystonia (Krauss, 2002 ; Krauss *et al*., 2003 ; Kupsch *et al*., 2003). Results of pallidal DBS in secondary dystonias (such as NBIA) are less conclusive (Volkmann and Benecke, 2002 ; Toda *et al*., 2004). The results are generally less helpful than those obtained in patients with primary dystonia (Eltahawy *et al.*, 2004). After a 1-year follow-up, Coubes found a 71% improvement in the clinical BFM score in a group of 15 patients with DYT1 dystonia, compared to a 31% improvement in a group of 21 patients with secondary dystonia (varied etiologies as perinatal anoxia, foeto-maternal incompatibility in the Rhesus system, PKAN syndrome, mitochondrial cytopathies, type 1 tyrosinemia, postanoxic encephalopathies) (Cif *et al*., 2003) The BFM score of our first patient improved by 65% after 18 months. This is a favourable outcome when compared to most results in secondary dystonia. This was also confirmed in other cases of genetically confirmed PKAN. Bilateral internal globus pallidus stimulation was performed in six patients with genetically confirmed PKAN who obtained a major and longlasting improvement of their painful spasms, dystonia and functional autonomy (Castelnau *et al*., 2005). Follow-up of larger patient series will be needed to evaluate the impact of the bipallidal DBS technique on both PANK2-mutation-positive and -negative NBIA patients.

REFERENCES

CAROD-ARTAL F. J., VARGAS A. P., MARINHO P. B., FERNANDES-SILVA T. V., PORTUGAL D. Tourettism, hemiballism and juvenile Parkinsonism : expanding the clinical spectrum of the neurodegeneration associated to panothenate kinase deficiency (Hallervorden Spatz syndrome). *Rev. Neuro.*, 2004, **38** : 327-31.

THOMAS M., HAYFLICK S. J., JANKOVIC J. Clinical Heterogeneity of Neurodegeneration With Brain Iron Accumulation (Hallervorden-Spatz Syndrome) and Pantothenate Kinase-Associated Neurodegeneration. *Mov. Disord.*, 2004, **19** : 36-42.

HAYFLICK S. J. Unraveling the Hallervorden-Spatz syndrome : pantothenate kinase-associated neurodegeneration is the name. *Curr. Opin. Pediatr.*, 2003, **15** : 572-7.

HALLERVORDEN J., SPATZ H. Eigenartige Erkrankung im extrapyramidalen System mit besonderer Beteiligung des Globus pallidus und der Substantia nigra : Ein Beitrag zu den Beziehungen zwischen diesen beiden Zentren. *Z Ges Neurol Psychiat*, 1922, **79** : 254-302.

WIGBOLDUS J. M., BRUYN G. W. Hallervorden-Spatz disease. In : VINKEN P. J., BRUYN G. W. (eds.). *Handbook of clinical neurology* : *diseases of the basal ganglia*, 1968, **6** : 604-631.

HAYFLICK S. J., WESTAWAY S. K., LEVINSON B. Genetic, Clinical, and Radiographic Delineation of Hallervorden-Spatz Syndrome. *N. Engl. J. Med.*, 2003, **348** : 33-40.

HALLIDAY W. The nosology of Hallervorden-Spatz disease. *J. Neurol. Sci.*, 1995, **134** : 88-91.

GRIMES D. A., LANG A. E., BERGERON C. Late adult chorea with typical pathology of Hallervorden-Spatz syndrome. *J Neurol. Neurosurg. Psychiatry*, 2000, **69** : 392-395.

RACETTE B. A., PERRY A., D'AVOSSA G., PERLMUTTER J. S. Late-onset neurodegeneration with brain iron accumulation type 1 : expanding the clinical spectrum. *Mov. Disord.*, 2001, **16** : 1148-52.

JANKOVIC J., KIRKPATRICK J. B., BLOMQUIST K. A., LANGLAIS P. J., BIRD E. D. Late-onset Hallervorden-Spatz disease presenting as familial parkinsonism. *Neurology*, 1985, **2** : 227-34.

DOOLING E. C., SCHOENE W. C., RICHARDSON E. P. Hallervorden-Spatz syndrome. *Arch. Neurol.*, 1974, **30** : 70-83.

WANG L. N., HUANG K. W., LIU Z. Y. Sporadic late-onset type of Hallervorden-Spatz disease presenting as parkinsonism in a Chinese patient. *Chin. Med. J.*, 1990, **103** : 686-688.

SETHI K. D., ADAMS R. J., LORING D. W., GAMMAL T. Hallervorden-Spatz Syndrome : Clinical and Magnetic Resonance Imaging Correlations. *Ann. Neurol.*, 1998, **24** : 692-694.

GALLUCCI M., CARDONA F., ARACHI M., SPLENDIANI A., BOZZAO A. *et al*. Follow-up MR studies in Hallervorden-Spatz disease. *J. Comput. Assist. Tomogr.*, 1990, **14** : 118-20.

GORDON N. Pantothenate kinase-associated neurodegeneration (Hallervorden-Spatz syndrome). *Eur. J. Paediatr. Neurol.*, 2002, **6** : 243-7.

SEIBEL M. O., DATE E. S., ZEINER H., SCHWARTZ M. Rehabilitation of patients with Hallervorden-Spatz syndrome. *Arch. Phys. Med. Rehabil.*, 1993, **74** : 328-9.

DRESSLER D., WITTSTOCK M., BENECKE R. Botulinum toxin for treatment of jaw opening dystonia in Hallervorden-Spatz syndrome. *Eur. Neurol.*, 2001, **45** : 287-8.

VERCUEIL L., KRACK P., POLLAK P. Results of deep brain stimulation for dystonia : a critical reappraisal. *Mov. Disord.*, 2002, **17** (suppl 3) : S89-93.

COUBES P., CIF L., FERTIT H. Electrical stimulation of the globus pallidus internus in patients with primary generalized dystonia : long-term results. *J. Neurosurg.*, 2004, **10** : 189-194.

KRAUSS J. K., LOHER T. J., WEIGEL R., CAPELLE H. H., WEBER S. Chronic stimulation of the globus pallidus internus for treatment of non-DYT 1 generalized dystonia and choreoathetosis : 2-year follow-up. *J. Neurosurg.*, 2003, **98** : 785-92.

KUPSCH A., KUEHN A., KLAFFKE S. Deep brain stimulation in dystonia. *J Neurol*, 2003, **250** (suppl. 1) : 147-52.

KRAUSS J. K. Deep brain stimulation for dystonia in adults Overview and developments. *Stereotact. Funct. Neurosurg.*, 2002, **78** : 168-82.

VOLKMANN J., BENECKE R. Deep brain stimulation for dystonia : patient selection and evaluation. *Mov. Disord. Suppl.*, 2002, **3** : S112-5.

TODA H., HAMANI C., LOZANO A. Deep brain stimulation in the treatment of dyskinesia and dystonia. *Neurosurg. Focus*, 2004, **17** : E2.

ELTAHAWY H. A., SAINT-CYR J., GILADI N., LANG A. E., LOZANO A. M. Primary dystonia is more responsive than secondary dystonia to pallidal interventions : outcome after pallidotomy or pallidal deep brain stimulation. *Neurosurgery*, 2004, **54** : 613-19.

CIF L., EL FERTIT H., VAYSSIERE N., HEMM S., HARDOUIN E. *et al*. Treatment of dystonic syndromes by chronic electrical stimulation of the internal globus pallidusi. *J. Neurosurg. Sci.*, 2003, **47** : 52-5.

CASTELNAU P., CIF L., VALENTE E. M., VAYSSIERE N., HEMM S. *et al*. Pallidal stimulation improves pantothenate kinase-associated neurodegeneration. *Ann. Neurol*, 2005, **57** : 613-4.

F. CLEMENT,
Hôpital Roger Salengro,
F-59037 Lille, France

L. DEFEBVRE,
Hôpital Roger Salengro,
F-59037 Lille, France
E-mail : freclement@yahoo.com
ldefebvre@chru-lille.fr.